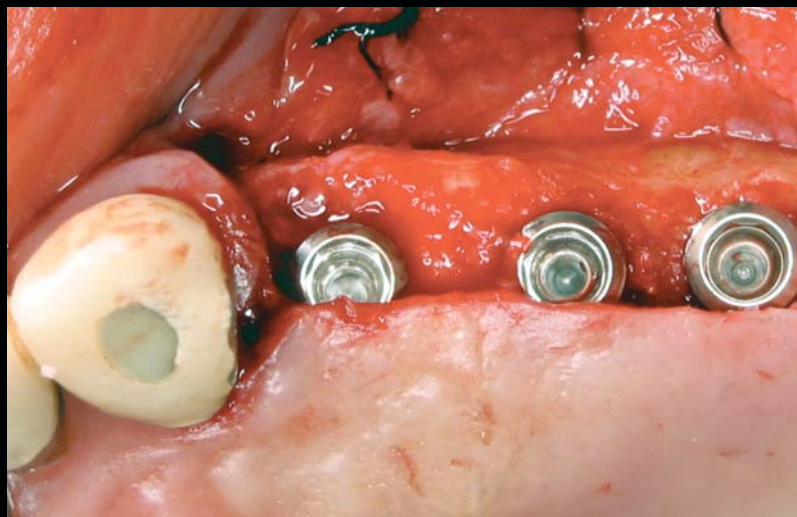


CONTINUING EDUCATION **XX**

TREATING THE ATROPHIC POSTERIOR MAXILLA BY COMBINING SHORT IMPLANTS WITH MINIMALLY INVASIVE OSTEOTOME PROCEDURES

Michael Toffler, DDS*

TOFFLER
18
5
JUNE

Edentulous sites in the posterior maxilla are often compromised by reduced bone volume, prohibiting the placement of 10-mm implants without sinus augmentation. The use of shorter implants minimizes the need for more extensive sinus floor elevation, thus reducing treatment duration and morbidity. Two implant designs are presented in combination with localized internal sinus floor elevation to restore the posterior maxilla. This simplified treatment modality can make implant rehabilitation of the atrophic posterior maxilla more accessible and more palatable to even the most reluctant patients and referring doctors.

Learning Objectives:

This article presents a series of cases in which two types of short implants are used to minimize or avoid sinus augmentation in cases with reduced subantral bone volume. Upon reading this article, the reader should:

- Become familiar with the clinical indications and techniques for the placement of short implants in the posterior maxilla.
- Realize the practical and clinical benefits this more conservative treatment approach offers.

Key Words: osteotome, sinus augmentation, implant surface modification, crown-to-implant ratio

*Attending Department of Periodontics Veterans' Administration Medical Center, New York, NY; private practice, New York, NY.

Michael Toffler, DDS, 116 Central Park South, Suite 3, New York, NY 10019
Tel: 212-581-4646 • E-mail: mtoffler@earthlink.net

Practical Procedures & AESTHETIC DENTISTRY

The patient with an edentulous posterior maxilla compromised by markedly reduced subantral bone height must accept the increased risk of complication, extended treatment duration, and heavier financial burden associated with implant-supported rehabilitation. The clinical challenge is exacerbated by postextraction ridge resorption and increased pneumatization of the maxillary sinus, which significantly reduces the available bone volume. This renders the ability to place an implant 10 mm or longer without invoking sinus-augmentation procedures impossible. Various techniques for sinus floor elevation have been reported using different graft materials in a delayed or simultaneous approach to implant placement.¹⁻⁸ The lateral window osteotomy (LWO) is the most commonly used technique for sinus augmentation,^{2,4} but it does have some disadvantages, including a higher cost, increased morbidity, risk of serious infection, and delayed healing time.⁹ As a less invasive alternative, osteotome techniques can obtain a localized elevation of the sinus floor through a 3-mm- to 6-mm-diameter crestal osteotomy, which minimizes the degree of flap elevation and thus eliminates the need for preparation of a larger bony window in the lateral aspect of the alveolus.^{5,8,10,11} An osteotome-mediated approach offers the advantages of a more conservative surgical entry, more localized augmentation of the sinus, a reduced degree of postoperative morbidity, and the ability to load the implants in a shorter time period.¹²

When there is adequate subantral bone for the primary stabilization of implants, osteotome-mediated sinus floor elevation (OMSFE) procedures procure 2 mm to 7 mm of localized sinus floor elevation, usually permitting the simultaneous placement of implants of 10 mm or greater in length.^{5,10,11} A multicenter study on the bone-added osteotome sinus floor elevation procedure showed that the survival rate was 96% when the residual subantral bone height (RSBH) was at least 5 mm and 85.7% when the RSBH was 4 mm or less.¹⁰ Toffler reported on 276 OMSFE procedures in 167 patients (with a mean RSBH of 7.1 mm) using four different screw-type implants.¹¹ The procedure resulted in a mean increase in bone height of 3.8 mm. The average implant length was 11.1 mm, with a mean functional time of 27.9 months. In patients with at least 5 mm of RSBH, the survival rate was 94.6%. This rate decreased to 73.3% for implants placed in areas in which the RSBH was 4 mm or less.¹¹

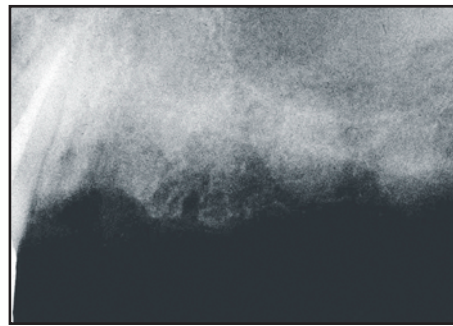


Figure 1. Preoperative radiograph 3 months after the loss of tooth #12(24) and the cantilevered prosthesis.

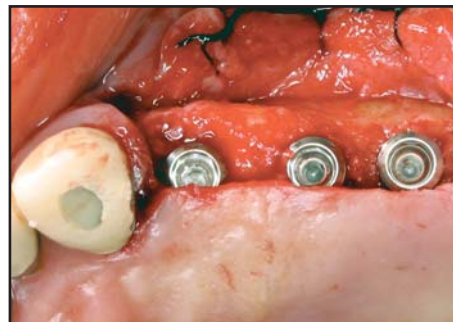


Figure 2. At sites #12 through #14(26), single-stage implants were placed with their smooth 1.8-mm collars positioned supracrestally

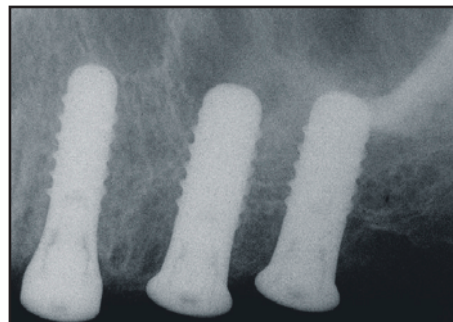

Figure 3. Immediate postoperative radiograph of implants at sites #12 through #14.

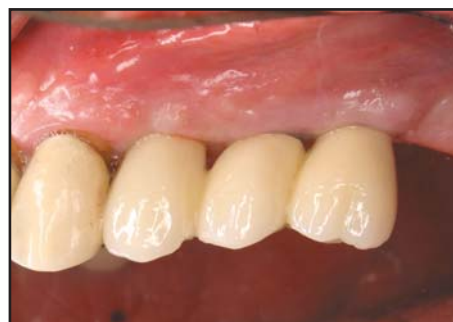

Figure 4. Four months postoperation, the implants were restored with a splinted, cemented prosthesis.

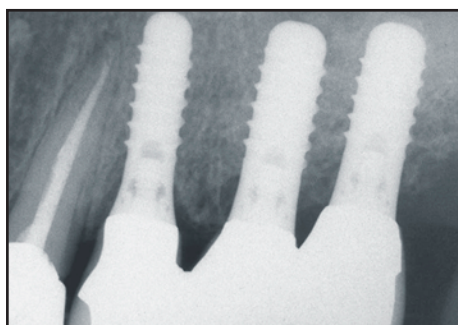


Figure 5. Periapical radiograph of implant-supported prosthesis that was taken 15 months after placement.

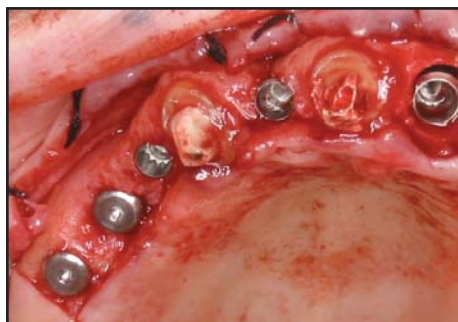

Figure 6. Implants were placed at sites #5(14), #7(12), and #9(21). At sites #3(16) and #4(15), implants were placed without grafting.

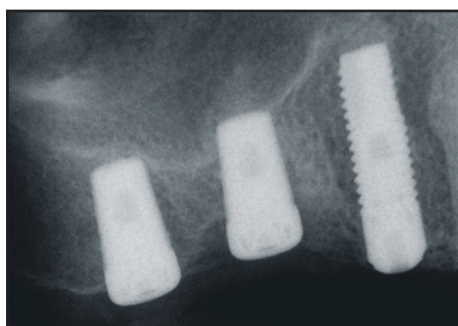


Figure 7. Immediate postoperative radiograph once the 5-mm x 7-mm implants were placed with osteotome-mediated sinus floor infraction.

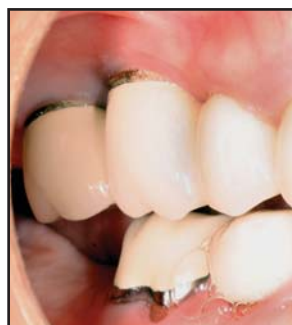

Figure 8. Individual cemented restorations at site #2(17) through #4.

Based on these studies, it would seem that in the more severely resorbed posterior maxilla (less than 5 mm RSBH), minimally invasive OMSFE with simultaneous implant placement is not the treatment of choice. A staged approach using a lateral window technique²⁴ or crestal core approach⁶⁸ would be preferred. Neither of these osteotome studies, however, incorporated short implants with a threaded SLA surface or tapered, sintered, porous-surfaced design, both of which have shown improved success rates in the posterior maxilla in lengths of 5 mm to 9 mm.¹³⁻¹⁷

Fugazzotto et al assessed the success and failure rates of 7-mm to 9-mm titanium plasma-sprayed (TPS) and sand-blasted, acid-etched, large-grit (SLA) implants used to replace maxillary first or second molars.¹⁴ A total of 979 implants were followed in function for up to 84 months and exhibited an overall success rate of 95.1%. No implants were placed at the time of tooth extraction or in conjunction with regenerative and/or sinus augmentation therapy. Nedir et al reported on a 7-year life table analysis on 528 TPS and SLA implants loaded for at least one year. In the posterior maxilla, 125 implants were placed with a mean length of 9.74 mm.¹⁶ Sinus perforation was not avoided, a penetration of 1 mm to 2 mm was tolerated, and standard insertion was performed when 5 mm of RSBH was available. The cumulative success rate was 99.4% and shorter implants did not have a greater failure rate than longer ones. Diserens et al performed a radiographic analysis of 44 implants with a TPS or SLA surface placed using transcresal sinus floor elevation.¹⁷ The mean RSBH was 5.78 mm and the mean implant length was 8.9 mm. All implants were considered to be successful after a minimum loading period of 200 days.

Deporter et al recently reported on 104 implants (the majority were 7 mm in length) in 70 patients, primarily placed at the maxillary first molar site.¹⁵ The mean initial subantral bone height before implant placement was 4.2 mm. Many of the sites had only 3 mm of RSBH and this had no apparent effect on implant integration and performance. After an average functional time of 3.14 years, only two implants were lost. The sintered porous-surfaced design of these implants (ie, Endopore, Innova Corp, Ontario, Canada) allowed for bone ingrowth and three-dimensional mechanical interlocking^{18,20} and, therefore, can be routinely used in lengths of 7 mm or less.^{18,19}

When considering the use of short implants in the compromised posterior maxilla, the insertion protocol

Practical Procedures & AESTHETIC DENTISTRY

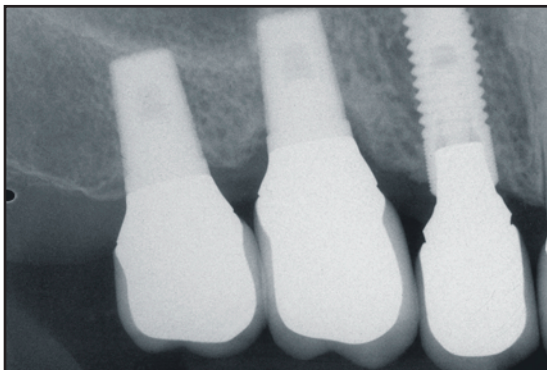


Figure 9. Five-month periapical radiograph of individual implant-supported restorations at sites #2, #3, and #4.

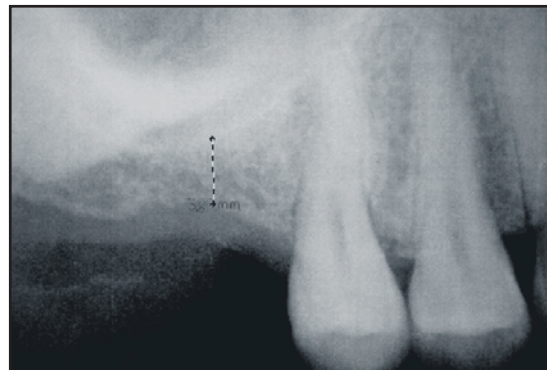


Figure 10. Case 3. Periapical radiograph revealed 4 mm of residual subantral bone height available to initially stabilize an implant at site #3.

should improve localized bone quality, maximize implant stability, and perform minor sinus floor elevation as necessary. The preservation of the remaining bone in the crestal cortical passage, as well as an improved bone-to-implant contact in the residual subantral bone, allows the selected short implant to successfully function with a significantly increased crown-to-implant ratio. The clinical application of shorter (7 mm to 10 mm) implants in the posterior maxilla serves to minimize the extent of sinus floor elevation required, which could be performed in most instances by a less invasive, bone-condensing, osteotome-mediated approach. This combined treatment will not only reduce surgical risks, surgical costs, and treatment duration, but also improve patient compliance with the recommended implant therapy.

Case Presentations

Case 1

A 71-year-old male presented for replacement of a lost cantilevered prosthesis in the position of tooth #11(23) through #13(25) due to the fracture of the distal abutment in site #12(24). The prosthesis was originally positioned to avoid implant placement and the associated sinus grafting. Three months after the loss of tooth #12, there was a RSBH of 12 mm at site #12, 7 mm at site #13, and 5 mm at site #14(26) (Figure 1). Previous consultation with an oral surgeon advised a lateral window approach with staged implant placement at site #14 and possibly #13, depending upon residual bone quality. Instead, the patient was given the option of placing implants at site #13 and #14, with 3 mm to 4 mm of OMSFE using a combination of autogenous bone and bovine bone mineral (ie, BioOss,

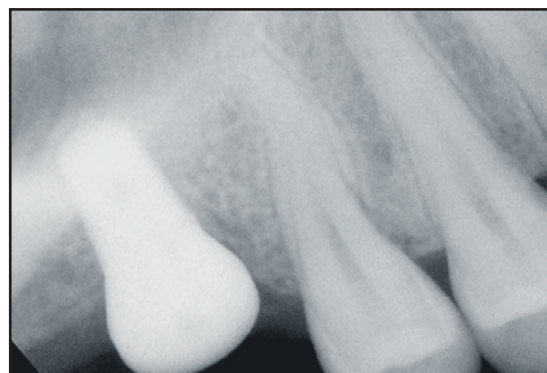

Figure 11. Immediate postoperative radiograph of 3 mm to 4 mm sinus elevation, which enabled the placement of a short implant using a single-stage protocol.

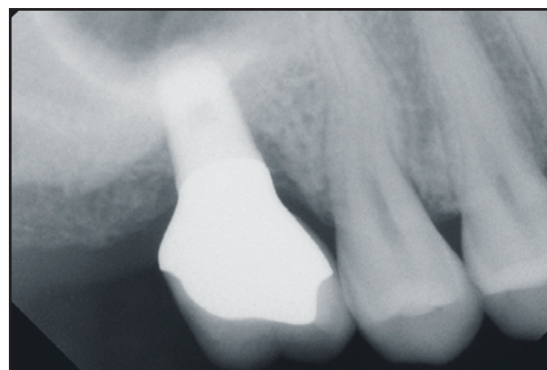


Figure 12. Periapical radiograph of implant-supported restoration at site #3 taken after 1 year in function.

Osteohealth, Shirley, NY). Single-stage implants with a smooth 1.8-mm collar were positioned supracrestally to maximize the preservation of the crestal cortical bone (Figures 2 and 3). Localized sinus floor elevation was evident at the distal sites. Four months later, the implants

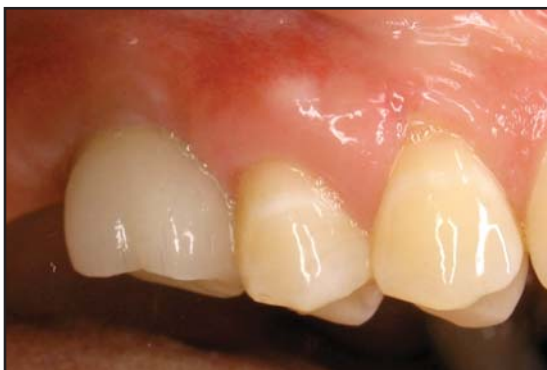

Figure 13. Cemented implant-supported restoration at site #3 as viewed at 6 months in function.

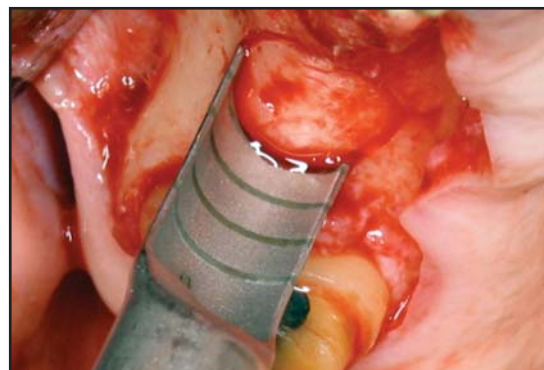


Figure 16. Insertion of a #6(13) core osteotome to directly infracture the sinus floor along the core's periphery.

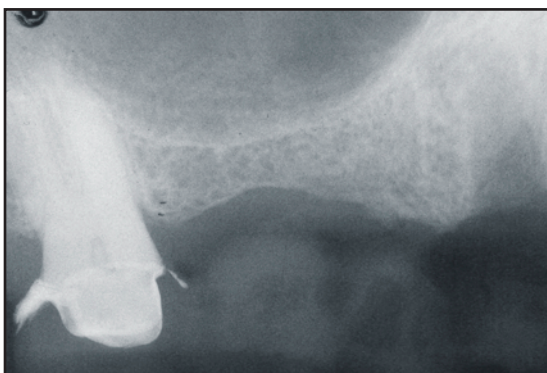


Figure 14. Case 4. Patient presented with a need for implant placement at site #3 through #5 as depicted by the radiograph.

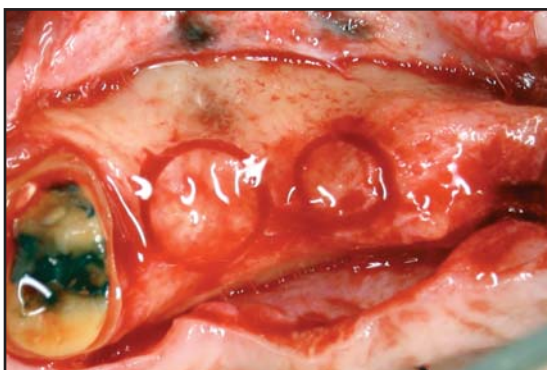


Figure 15. Staged implant placement using a crestal core elevation procedure.

were restored with a splinted, cemented prosthesis (Figures 4 and 5). The combination of minimally invasive sinus floor elevation and shorter implants expedited treatment and also significantly reduced the patient's surgical costs.

Case 2

A 70-year-old female presented with a long history of chronic sinusitis and declined placement of graft material into the sinus to allow for the insertion of longer implants at site #3(16) and #4(15), where there was a RSBH of 6 mm. Astra ST (AstraTech, Lexington, MA) implants that measured 4 mm to 5 mm in diameter and 13 mm in length were placed at site #5(14), #7(12), and #9(21). At site #3 and #4, 5-mm × 7-mm implants were placed with osteotome-mediated sinus floor infracture only and no grafting material (Figures 6 and 7). Five months later, the implants were uncovered and healing abutments were placed. Three weeks after this step was completed, cementation of individual restorations on both the implants and the remaining natural teeth (Figures 8 and 9) was performed.

Case 3

A 29-year-old female sought a second opinion for possible implant placement at site #3 after being advised an LWO would be required and a single 11-mm to 13-mm, wide-body implant could be placed 5 to 7 months later. The periapical radiograph revealed 4 mm of RSBH available to initially stabilize an implant at site #3 (Figure 10). Using OMSFE and a 1:1 mixture of bovine bone mineral and autogenous bone, a localized internal sinus floor elevation of 3 mm to 4 mm enabled the simultaneous placement of a 5-mm × 7-mm tapered, sintered, porous-surfaced implant (Figure 11). Six months later, a cemented restoration was placed (Figures 12 and 13). This minimally invasive treatment has not only reduced treatment time and morbidity, but has significantly reduced this patient's financial burden.

Practical Procedures & AESTHETIC DENTISTRY

Case 4

A 70-year-old female required implant placement at site #3 through #5 (Figure 14). There was a RSBH of 2 mm to 4 mm at site #3 and #4, where staged implant placement was performed using a crestal core elevation procedure (Figure 15).⁶ A 6-mm-diameter core at site #3 and a 4-mm-diameter core at site #4 were prepared to depths of 1 mm to 3 mm prior to introduction of a core osteotome (Figure 16) to directly infracture the sinus floor along the core's periphery (Figure 16). This peripheral infracture facilitates apical displacement of the cores to the level of the sinus floor with 4-mm and 6-mm diameter osteotomes (Figure 17). Bovine bone mineral was grafted to the osteotomies and apically displaced, resulting in 5 mm to 6 mm of localized sinus floor elevation (Figure 18). The core osteotomies and residual extraction defect at site #5 were covered with an e-PTFE membrane stabilized by titanium tacks. Five months later, SLA implants that measured 4.1 mm to 4.8 mm in diameter and 10 mm in length were placed at site #3 and #4 and a 4.1-mm x 12-mm implant was placed at site #5 (Figure 19). The implants were restored 18 weeks later with a cement-retained, splinted prosthesis (Figure 20).

Discussion

The sinus graft is considered to be a safe treatment modality in which complications are uncommon;²¹ however, when the procedure is performed using a LWO it is a relatively complex operation in comparison to simple implant placement. The longer duration and the additional tissues involved increase its potential for postoperative complications.²² The improved predictability of short SLA implants,^{13,14,16,17} sintered and porous-surfaced implants,^{15,18,19,20} as well as HA-coated^{21,23} and oxidized²⁴ implants placed in the posterior maxilla should reduce the necessity of more extensive sinus grafting. This leads to a decrease in treatment duration and the incidence of complications. The reduced bone volume required for shorter implants would, in turn, expand the clinical applications for the less invasive OMSFE to allow for the placement of implants that are 6 mm to 10 mm in length. Modifications to this localized internal approach allow for both simultaneous and staged implant placement at sites with a RSBH of at least 2 mm.^{6,8,15,17} The utilization of these minimally invasive surgical procedures results in increased case acceptance with reduced treatment duration, trauma, and cost. This was made evident by case

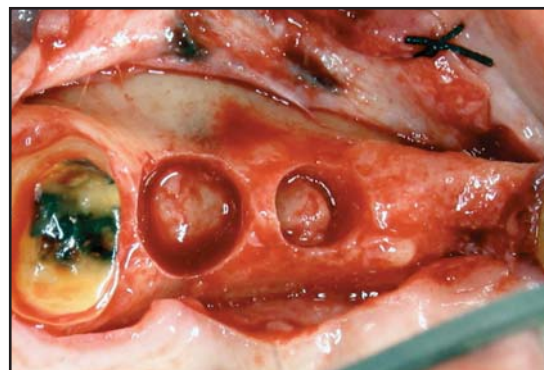


Figure 17. Using a 4-mm- and 6-mm-diameter osteotome, both cores were imploded to the level of the sinus floor.

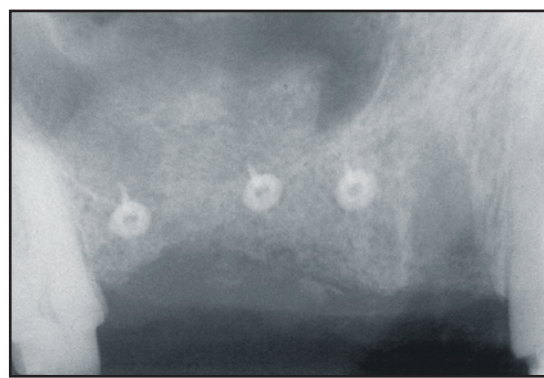

Figure 18. Immediate postoperative radiograph of site #3 through #5 showing localized sinus floor elevation at site #3 and #4 and the residual extraction defect at site #5.

reports where 7-mm-long sintered, porous-surfaced and 8-mm to 10-mm SLA implants were placed with minimal sinus intrusion.

In all cases, the ability to achieve long-term success with implants is intrinsically related to the amount of implant surface in contact with bone.²⁵ The addition of a roughened surface texture to machined threads is known to enhance overall clinical performance, particularly in areas of reduced bone density (ie, the posterior maxilla).²⁶ Modifications of the implant surface (eg, etching, blasting, porosity) have improved the retention between the implant and the bone by enlarging the contact surface and by increasing the biomechanical interlocking between the implant and the bone.^{26,27} These osseointegrative surfaces effectively reduce the length of the implant needed to function under the occlusal load generated in the posterior maxilla.

A clinical concern regarding the utilization of short implants is the alleged unfavorable crown-to-implant ratio

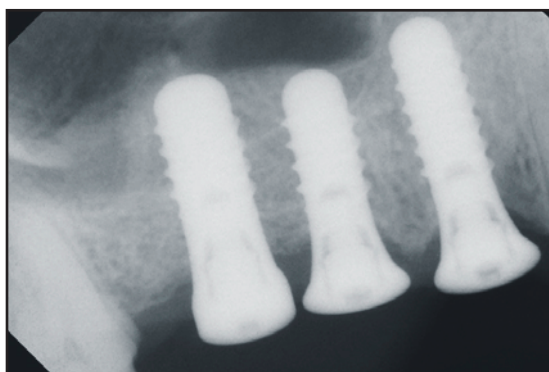


Figure 19. Five months postoperation, solid screw SLA implants were placed at grafted sites #3 and #4. A longer implant was placed at site #5.

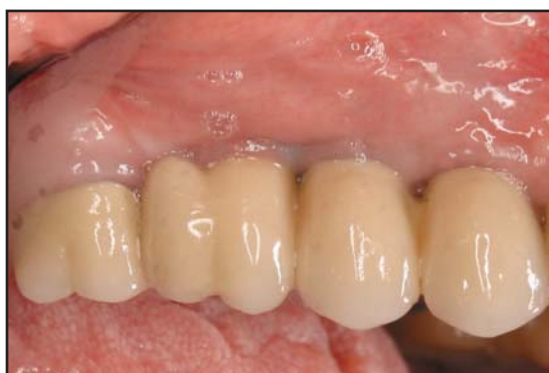

Figure 20. Six months after implant placement, patient has a cement-retained, splinted prosthesis on implants at site #3 through #5.

(ie, beyond 1.0), which increases the occlusal stresses and potential risk for implant or component failure. The selection of short implants, which provide a maximal implant-to-bone surface area and more efficient fixation, could potentially counteract the unfavorable crown-to-implant ratio and the associated stresses.

Nedir et al reported on 528 short SLA implants placed in the posterior maxilla.¹⁶ The crown-to-implant ratio was 1.8 to 1.97, and no failures were experienced after at least 1 year of loading. Rokni et al published a retrospective analysis of the crown-to-root implant ratios from two previous clinical trials using tapered porous implants (ie, Endopore, Innova, Ontario, Canada) that indicated the crown-to-implant ratio had no significant effect on crestal bone levels or success when short implants were used.²⁸ This would seem to indicate that the dimensions of these implants were not as important as actual bone ingrowth and the resulting three-dimensional mechanical interlocking with the sintered porous-

surfaced design.^{18,19,27} Such 5-mm- to 7-mm-long implants do not require splinting of multiple implant units and perform very well in low density bone.²⁸⁻³⁰

Conclusion

The use of short implants, 7- to 8 mm in length, in combination with minimally invasive sinus floor elevation, where necessary, provides clinicians with more conservative treatment options, and helps minimize treatment duration, costs, and trauma. These benefits, along with the safe and predictable use of short implants, should make implant therapy accessible to a greater number of patients and practitioners. Increased use of this simplified, minimally invasive approach to implant placement in the deficient maxillary premolar or molar region may allow a larger segment of the patient population to avoid uncomfortable, removable appliances, or long-span fixed prosthesis.

Acknowledgment

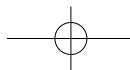
The author expresses his gratitude to surgical assistants Grisel Crespo, Opal Lumbsden, Tracey Lindsay, and Jezel Best and restorative dentists Dr. Jeffrey Clويدt, Dr. Bruce Valauri, Dr. Louis Siegelman, and Dr. Marc Tisch for their contributions to the success of the cases depicted. The core osteotome used herein was designed by the author and manufactured by H & H Co., Ontario, CA, from which he receives a portion of the sales of all instruments he has designed for this company.

References

- Wallace SS, Froum SJ. Effect of maxillary sinus augmentation on the survival of endosseous dental implants. A systematic review. *Ann Periodontol* 2003;8(1):328-343.
- ten Bruggenkate CM, van den Bergh JP. Maxillary sinus floor elevation: A valuable pre-prosthetic procedure. *Periodontol* 2000 1998;17:176-182.
- Smiler DG. The sinus lift graft: Basic techniques and variations. *Pract Periodont Aesthet Dent* 1997;9(8):885-893.
- Garg AK, Quinones CR. Augmentation of the maxillary sinus: A surgical technique. *Pract Periodont Aesthet Dent* 1997;9(2):211-219.
- Summers RB. The osteotome technique: Part 3 – Less invasive methods for elevating the sinus floor. *Compendium* 1994;15(6):698-704.
- Toffler M. Staged sinus augmentation using a crestal core elevation procedure (CCE) to minimize membrane perforation. *Pract Proced Aesthet Dent* 2002;14(9):767-774.
- Fugazzotto PA. Immediate implant placement following a modified trephine/osteotome approach: Success rates of 116 implants to 4 years in function. *Int J Oral Maxillofac Implants* 2002;17(1):113-120.
- Fugazzotto PA. The modified trephine/osteotome sinus augmentation technique: Technical considerations and discussion of indications. *Implant Dent* 2001;10(4):259-264.
- Regev E, Smith RA, Perrott DH, Pogrel MA. Maxillary sinus complications related to endosseous implants. *Int J Oral Maxillofac Implants* 1995;10(4):451-461.

Practical Procedures & AESTHETIC DENTISTRY

10. Rosen PS, Summers R, Mellado JR, et al. The bone-added osteotome sinus floor elevation technique: Multicenter retrospective report of consecutively treated patients. *Int J Oral Maxillofac Implants* 1999;14(6):853-858.
11. Toffler M. Osteotome-mediated sinus floor elevation: A clinical report. *Int J Oral Maxillofac Implants* 2004;19(2):266-273.
12. Fugazzotto P. Augmentation of the posterior maxilla: A proposed hierarchy of treatment selection. *J Periodontol* 2003;74(11):1682-1691.
13. ten Bruggenkate CM, Asikainen P, Foitzik C, et al. Short (6-mm) nonsubmerged dental implants: Results of a Multicenter clinical trial of 1 to 7 years. *Int J Oral Maxillofac Implants* 1998;13(6):791-798.
14. Fugazzotto PA, Beagle JR, Ganeles J, et al. Success and failure rates of 9 mm or shorter implants in the replacement of missing maxillary molars when restored with individual crowns: Preliminary results 0 to 84 months in function. A retrospective study. *J Periodontol* 2004;75(2):327-332.
15. Deporter D, Todescan R, Caudry S. Simplifying management of the posterior maxilla using short, porous-surfaced dental implants and simultaneous indirect sinus elevation. *Int J Periodont Rest Dent* 2000;20(5):476-485.
16. Nedir R, Bischof M, Briaux JM, et al. A 7-year life table analysis from a prospective study on ITI implants with special emphasis on the use of short implants. Results from a private practice. *Clin Oral Implants Res* 2004;15(2):150-157.
17. Diserens V, Mericske E, Mericske-Stern R. Radiographic analysis of the transcrestal sinus floor elevation: Short-term observations. *Clin Implant Dent Relat Res* 2005;7(2):70-78.
18. Hagi D, Deporter DA, Pilliar RM, Arenovich T. Targeted review of study outcomes with short (< or = 7 mm) endosseous dental implants placed in partially edentulous patients. *J Periodontol* 2004;75(6):798-804.
19. Pilliar RM. Overview of surface variability of metallic endosseous implants: Textured and porous surface-structured designs. *Implant Dent* 1998;7(4):305-314.
20. Deporter DA, Todescan R, Watson PA, et al. Use of the Endopore dental implant to restore single teeth in the maxilla: Protocol and early results. *Int J Oral Maxillofac Implants* 1998;13(2):263-272.
21. Ziccardi VB, Betts NJ. Complications of maxillary sinus augmentation. In: Jensen OT, ed. *The Sinus Bone Graft*, 1st ed. Chicago: Quintessence Books;1999:201-208.
22. Schwartz-Arad D, Herzberg R, Dolev E. The prevalence of surgical complications of the sinus graft procedure and their impact on implant survival. *J Periodontol* 2004;75(4):511-516.
23. Griffin TJ, Cheung WS. The use of short, wide implants in posterior areas with reduced bone height: A retrospective investigation. *J Prosthet Dent* 2004;92(2):139-144.
24. Renouard F, Nisand D. Short implants in the severely resorbed maxilla: A 2-year retrospective clinical study. *Clin Implant Dent Relat Res* 2005;7(suppl 1):S104-S110.
25. Cochran DL, Nummikoski PV, Higginbottom FL, et al. Evaluation of an endosseous titanium implant with a sandblasted and acid-etched surface in the canine mandible: Radiographic results. *Clin Oral Implants Res* 1996;7(3):240-252.
26. Cochran DL. A comparison of endosseous dental implant surfaces. *J Periodontol* 1999;70(12):1523-1539.
27. Pilliar RM. Overview of surface variability of metallic endosseous implants: Textured and porous surface-structured designs. *Implant Dent* 1998;7(4):305-314.
28. Rokni S, Todescan R, Watson P, et al. An assessment of crown-to-root ratios with short sintered porous-surfaced implants supporting prostheses in partially edentulous patients. *Int J Oral Maxillofac Implants* 2005;20(1):69-76.
29. Deporter DA, Todescan R, Watson PA, et al. A prospective human clinical trial of Endopore dental implants in restoring the partially edentulous maxilla using fixed prostheses. *Int J Oral Maxillofac Implants* 2001;16(4):527-536.
30. Deporter DA, Pilliar RM, Todescan R, et al. Managing the posterior mandible of partially edentulous patients with short, porous-surfaced dental implants: Early data from a clinical trial. *Int J Oral Maxillofac Implants* 2001;16(5):653-658.



CONTINUING EDUCATION (CE) EXERCISE No. X



To submit your CE Exercise answers, please use the answer sheet found within the CE Editorial Section of this issue and complete as follows: 1) Identify the article; 2) Place an X in the appropriate box for each question of each exercise; 3) Clip answer sheet from the page and mail it to the CE Department at Montage Media Corporation. For further instructions, please refer to the CE Editorial Section.

The 10 multiple-choice questions for this Continuing Education (CE) exercise are based on the article "Treating the atrophic posterior maxilla by combining short implants with minimally invasive osteotome procedures," by Michael Toffler, DDS. This article is on Pages 000-000.

1. Implant placement in the posterior maxilla is complicated by which of the following?

- a. Poor bone quality.
- b. Sinus pneumatization.
- c. Postextraction ridge resorption.
- d. All of the above.

2. Which of the following is a disadvantage of the lateral window osteotomy?

- a. Unpredictable success rate.
- b. Minimal evidence-based support.
- c. Poor access to repair membrane perforations.
- d. More extensive flap elevation and postsurgical morbidity compared to an osteotome-mediated approach.

3. Which of the following is true of osteotome techniques?

- a. They decrease localized bone density.
- b. They can achieve a localized sinus floor elevation of 2 mm to 7 mm.
- c. They have an increased risk for postsurgical complications compared to the lateral window approach.
- d. They are the most commonly used technique for sinus floor elevation in the atrophic posterior maxilla.

4. The residual subantral bone is essential to the implant's primary stability. It has no effect on the success of implants placed with osteotome procedures.

- a. Only the first statement is true.
- b. Only the second statement is true.
- c. Both statements are true.
- d. Neither statement is true.

5. Modifications to the short implant surface that improve clinical success include which of the following?

- a. HA coating.
- b. Sand blasting and acid etching.
- c. Increasing porosity with a sintered-porous surface.
- d. All of the above.

6. Which of the following is true of short implants?

- a. They are used to improve the crown-to-implant ratio.
- b. They have historically been shown to be as successful as longer implants.
- c. They should be used in narrow diameters to improve success rates in the posterior maxilla.
- d. They should be used with modified surfaces to improve bone-implant contact surface area.

7. Which is the exception to what the insertion protocol for short implants in the posterior maxilla should do?

- a. Improve localized bone density.
- b. Minimize the use of osteotomes in poorer quality bone.
- c. Achieve good primary implant stability.
- d. Allow for localized sinus floor elevation.

8. The clinical application of short implants in combination with minimally invasive sinus floor elevation should do which of the following?

- a. Reduce surgical risks.
- b. Reduce treatment duration.
- c. Improve patient compliance with the recommended therapy.
- d. All of the above.

9. Which is the primary clinical regarding with the use of short implants?

- a. The ability of the implant to successfully function with an unfavorable crown-implant ratio and the associated occlusal stresses.
- b. They are more difficult to place than longer implants.
- c. Achieving initial osseointegration.
- d. Increased incidence of infection.

10. Which describes the ideals of implant therapy?

- a. It should be minimally invasive.
- b. It should be affordable.
- c. It should be predictable.
- d. All of the above.

