

Minimally Invasive Sinus Floor Elevation Procedures for Simultaneous and Staged Implant Placement

Michael Toffler, D.D.S.

Abstract

Osteotome techniques are used as a less invasive alternative to the lateral window osteotomy to increase the volume of bone in the posterior maxilla. Implants may be placed simultaneously for four to six months after performing osteotome-mediated sinus floor elevation, depending upon the residual crestal bone remaining beneath the sinus floor. This article describes the clinical indications and techniques for localized internal sinus elevation using osteotomes. The incorporation of this minimally invasive crestal approach to sinus augmentation into the clinical practice results in increased case acceptance with reduced treatment duration, trauma and cost.

IMPLANT PLACEMENT in the posterior maxilla is frequently complicated by an inadequate posterior alveolus and increased pneumatization of the maxillary sinus, creating close approximation of the sinus to the crestal bone.¹ Periodontal disease is a major contributor to this localized bone deficiency, frequently causing the loss of maxillary molars with significant resorption of alveolar bone. Atrophic changes follow as a result of the absence of osseous stimulation previously provided by the posterior dentition. The subsequent insertion of a removable prosthesis will exert non-physiologic pressure

on the ridge, contributing to further bone resorption. In addition, edentulous-related maxillary sinus pneumatization caused by osteoclastic erosion of the periosteal sinus floor leads to progressive hollowing out of the alveolar process from the apical aspect.² This destructive series of events often results in bone dimensions that are inadequate for the placement of properly proportioned and positioned implants. To combat these anatomical limitations, sinus floor elevation has become a common procedure to increase the volume of bone in the posterior maxilla, producing reliable long-term results in oral implant rehabilitation.³⁻⁷

Various techniques for sinus augmentation have been reported using different graft materials in a delayed or simultaneous approach to implant placement.⁸⁻¹⁰ The lateral window approach is the most commonly used and reported technique for sinus augmentation⁹⁻¹¹ (Figure 1). It has been recommended that the procedure be performed with simultaneous implant placement when at least 5 mm of residual sub-sinus alveolar bone height (RSBH) is present.^{4,5,7,10,11} When less than 5 mm RSBH exists, primary implant stability may be compromised, and implants are placed in a staged fashion at least three to four months later, depending upon the type of graft material and volume of bone augmentation.

As a less invasive alternative, osteotome techniques can obtain a localized elevation of the sinus floor through a 3 mm to 6 mm diameter crestal osteotomy,^{8,12-20} thus eliminating the need for preparation of a larger bony window in the lateral aspect of the alveolus and its

Dr. Toffler has designed osteotomes for both the OMSFE and CCE procedures and receives remuneration from their sale.

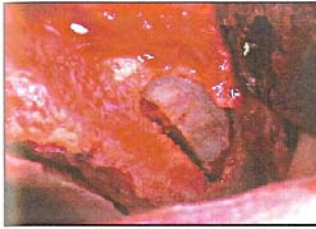


Figure 1. Lateral window preparation in left posterior maxilla just prior to grafting for sinus floor elevation at site with 2 mm of residual sub-sinus bone height (RSBH).

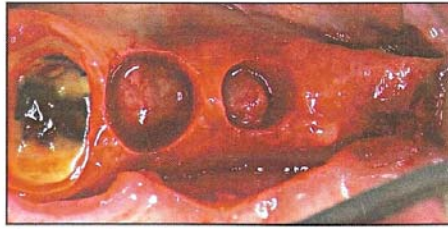


Figure 2. At site #3, 6 mm crestal core has been elevated for staged sinus floor elevation. At site #4, 4 mm core of bone has been prepared and will be removed, morselized and incorporated into graft mixture. Implants will be placed at sites #3, 4 and 5 in 6 months.



Figure 3. Set of end-cutting, rapid-expansion-limited-bone (RELB) osteotomes measuring 2 to 5.5 mm in diameter with depth markings at 4, 5, 6, 8 and 10 mm.

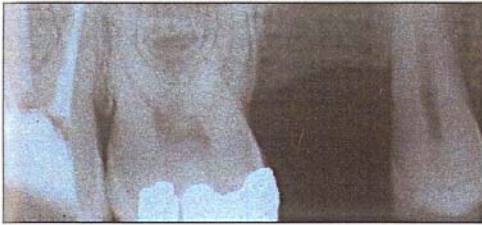

Figure 4. At site #4 there is 6 to 7 mm of RSBH.




Figure 5. 4 x 11.5 mm naturally tapered screw implant has been placed with 4 to 5 mm of localized sinus floor elevation.

subsequent rotation to apically displace the sinus (Figure 2). Initially proposed by Summers,^{12,20} this technique offers the advantages of a more conservative surgical entry, more localized augmentation of the sinus, a lesser degree of postoperative morbidity and an ability to load the implants in a shorter time period than that necessary when employing a lateral window approach to sinus augmentation.³

Osteotome-mediated sinus floor elevation (OMSFE) is performed using a crestal approach, common to standard implant surgery, with little or no contact between the osteotomes and Schneiderian membrane, which reduces the risk of complications.¹³ In these techniques, end-cutting osteotomes are used as an alternative to standard drilling (Figure 3). They gradually expand the osteotomy, compressing and apically displacing cancellous maxillary bone within the confines of the cortical plates and thus improving localized bone density.²⁰ This localized compaction of bone enhances the implant's primary stability and increases the bone-to-implant contact ratio in the early phase of treatment.²¹ When there is adequate bone for primary stabilization of the implant (5 mm or more), OMSFE will successfully achieve 2 mm to 7 mm of localized sinus floor elevation with simultaneous implant placement²² (Figures 4-5).

In a retrospective analysis of consecutive cases from nine clinicians in eight centers, the fate of 174 implants placed in 101 patients was evaluated.²³ Seven types of implants were placed employing a bone-added osteotome sinus floor elevation (BAOSFE) procedure in combination with a variety of graft materials. The average loading time for all the implants was 20.2 months (range 6 to 66 months). The survival rate was 96% when the residual sub-

sinus bone height (RSBH) was 5 mm or more, and 85.7% when the RSBH was 4 mm or less. Toffler²² reported on 276 OMSFE procedures in 167 patients using autogenous and bovine bone mineral along with four different screw-type implants. Of the 276 implants placed, 240 had been loaded for an average of 27.9 months (range 1 to 84 months). In patients with at least 5 mm of RSBH, the survival rate was 94.6%. This rate dropped to 73.3% for implants placed in areas with a RSBH of 4 mm or less. These reports clearly demonstrate that in cases of severely resorbed maxillae, minimally invasive sinus floor elevation with simultaneous implant placement using osteotomes would not be the treatment of choice. A two-stage procedure using a lateral window technique^{6,11} or a crestal core approach^{16,19} would be more predictable.

The crestal core elevation (CCE) procedure has been developed as an alternative to the lateral window approach in the more severely resorbed posterior maxilla where there is inadequate crestal bone present for primary stabilization of implants.¹⁷ In this procedure, trephined crestal bone cores, 5 mm to 6 mm in diameter are imploded with specially designed core osteotomes to raise the sinus floor prior to graft augmentation (Figure 6). Graft material is repeatedly added to the osteotomy and imploded with osteotomes to the original level of the sinus floor. This apically displaces the core and graft mixture, relocating the sinus floor. The osteotomy is covered with a barrier membrane and the tissues primarily closed. Six months later, implants are placed into osteotomies prepared with a combination of drills and osteotomes to further improve localized bone density.

The author has effectively used the CCE procedure as a less invasive

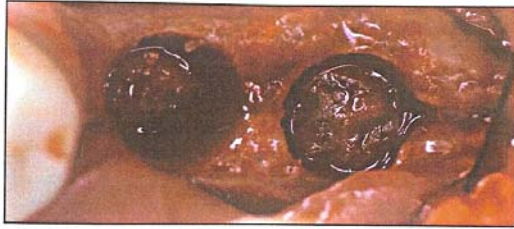

Figure 6. Two 5 mm diameter cores have been imploded to level of sinus floor at sites #14 and 15.

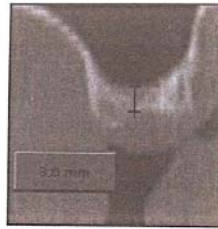


Figure 7. Scan of maxillary left first molar site with ridge width of 8 to 9 mm and RSBH of 3 to 4 mm. Staged sinus floor elevation will be performed using crestal core elevation (CCE).

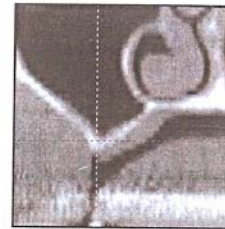


Figure 8. Scan of maxillary molar site demonstrating minimal ridge width and less than 2 mm of RSBH. Lateral window approach will be required for sinus floor elevation.

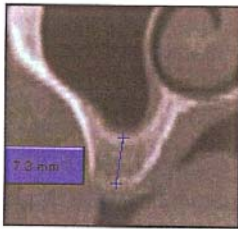


Figure 9. Scan of maxillary 2nd bicuspid site with adequate ridge width and height for simultaneous OMSFE and implant placement.

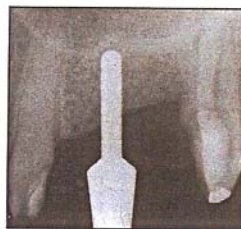


Figure 10. Radiographic verification of working depth after preparation with 2.3 mm drill.

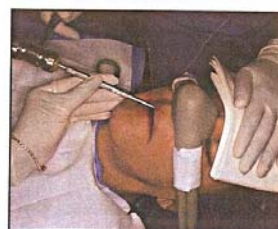

Figure 11. Firm support of patient's head is required during malleting procedure.

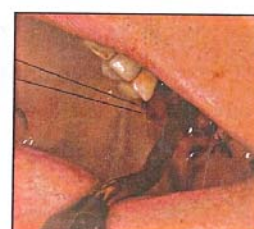

Figure 12. RELE osteotomy with 30-degree offset improves access to maxillary 1st and 2nd molar sites.

alternative to the lateral window osteotomy (LWO) for staged sinus floor elevation at sites where the ridge width is 6 mm or more and the RSBH is 2 mm to 5 mm¹⁷ (Figure 7). At sites where the ridge has narrowed and less than 2 mm of RSBH is present (Figure 8), a LWO is still the author's preferred method for sinus augmentation.

This article presents the surgical techniques for both OMSFE with simultaneous implant placement and CCE for staged implant placement in the posterior maxilla.

Minimally Invasive Sinus Floor Elevation Procedures

Osteotome-Mediated Sinus Floor Elevation with Simultaneous Implant Placement

All patients must sign an informed consent. Patients with systemic diseases exhibiting risk factors for surgical procedures, as well as patients with untreated periodontitis or sinusitis, are excluded from this procedure. OMSFE is indicated at maxillary molar and premolar sites with a RSBH of 4 mm to 10 mm (Figure 9). Treatment of the posterior maxilla is carried out under local anesthesia. Patients are instructed to take 2.0 g of amoxicillin or 600 mg of clindamycin one to two hours prior to surgery. If the patient requests it, nitrous oxide and/or triazolam (0.25 mg) are also used.

A beveled crestal incision is made with full thickness flap reflection to reveal the alveolar crest. The proposed implant site is first clearly marked with a 2 mm round drill followed by a 2 mm

twist drill to a depth of 2.5 mm to 5 mm. A 2 mm guide pin is then placed to verify implant position relative to the planned restoration. A 2.0 mm or 2.3 mm twist drill is then advanced to a depth that is 0.5 mm to 1 mm from the sinus floor (working depth), as measured from the preoperative radiograph. This ideal sub-sinus position is confirmed radiographically prior to proceeding (Figure 10). The osteotomy is then gradually expanded with a combination of drills and concave-tipped osteotomes inserted to the working depth.

In softer bone, the osteotomy will be widened with osteotomes to maximize the compaction of trabecular bone to improve localized bone density. The patient's head is stabilized while malleting the osteotomes by placing firm pressure on the forehead (Figure 11). At first and second molar sites, it is frequently necessary to use osteotomes with a 30-degree offset to improve access and perpetuate ideal restorative positioning of the implant (Figure 12). The final diameter of the osteotomy is 0.5 mm to 1.2 mm smaller than the implant diameter to maximize primary stability. If a tapered implant is used, implant site preparation is modified based on intended implant length, degree of taper and coronal implant diameter.²² The final osteotome, which is .5 mm to 1.2 mm less than the apical implant diameter, is then used to punch out the cortical plate of the sinus floor with the adherent membrane (Figure 13). Direct fracture with an osteotome does increase the risk for membrane perforation, but the distinct tactile and auditory changes associated with sinus floor encroachment allow the more

experienced clinician to modify the applied malleting force, resulting in a more controlled infracture without perforation.²²

Immediately after infracture, the implant site is evaluated for perforation of the sinus membrane by the Valsalva maneuver. If a perforation is detected (Figure 14), no graft material is added, and a collagen sponge (*CollaTape, Zimmer Products, Carlsbad CA*) is introduced in advance of an implant that is no longer than 2 mm to 3 mm more than the RSBH (Figure 15). If this does not allow for the placement of an implant at least 8.5 mm in length, the site is abandoned, and implant placement is delayed for three months. If the membrane has remained intact, a collagen sponge is inserted into the osteotomy and compressed apically prior to initiating the grafting procedure. Columns of a graft mixture, autogenous and anorganic bovine bone (*Bio-Oss*) in varied percentages, are then added to the osteotomy and displaced to working depth (Figure 16). Each 4.0 mm to 5.0 mm column of bone is used to create 1 mm of localized sinus floor elevation. This procedure is performed until adequate elevation has been achieved to accommodate the selected implant length. The osteotomy is then half-filled in advance of the implant, with the implant acting as the final osteotome.

A periapical radiograph is taken immediately after implant placement to confirm graft containment (Figure 17). If the implant is placed in a submerged fashion, it is uncovered in four to six months and restored three weeks later. If a single-stage protocol is used, the restorative treatment is initiated after four to six months.

Crestal Core Elevation Procedure for Staged Implant Placement

Patients are informed of all the potential risks, benefits and treatment alternatives prior to signing a written consent. Radiographic site analysis is usually performed with a panoramic and periapical radiograph. Patients with 2 mm to 5 mm of RSBH and 6 mm or more ridge width may be treated using the CCE procedure. Preoperative antibiotics are administered as described with the OMSFE procedure. Patients are instructed to rinse with 0.12% chlorhexidine for one minute prior to surgery.

A crestal incision beveled toward the palate is made throughout the edentulous area. An anterior-releasing incision is made at the mesial aspect of the most anterior tooth bordering the edentulous area. The posterior-releasing incision is placed distal to the tuberosity to access autogenous bone for grafting. Core preparation is initiated with 5 mm or 6 mm internal diameter trephines with markings at 2, 4, 6 and 8 mm (*H & H Co, Ontario, CA*). Care is taken to leave 1 mm of bone buccal and palatal to the core when possible (Figure 18). The core is prepared to the desired "working depth" of 1 mm from the sinus floor in the area of most limited RSBH. The one-third round #5 or #6 core osteotome (*H & H Co, Ontario, CA*) is malleted while the instrument is rotated around the core boundary (Figure 19). The instrument is designed with a 0.5 mm-thick curved tip that fits within the borders of the core preparation (Figure 20).

While gently malleting the core osteotome, the clinician retains the tactile sensation lost when using a trephine in close approximation to the sinus floor. The sinus floor has now been directly infractured along the borders of the core to facilitate apical displacement.

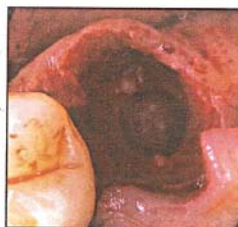

Figure 13. Direct infracture of sinus floor with 4 mm diameter osteotome immediately after extraction of tooth #13.




Figure 14. Radiographic confirmation of sinus membrane perforation at site #3.

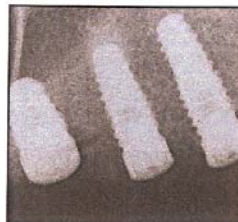


Figure 15. After placement of collagen sponge, 5 x 8.5 mm tapered screw implant was placed at site #3. No graft material is utilized at perforated site.

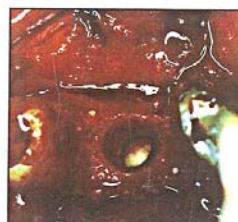


Figure 16. Graft mixture has been apically displaced to working depth.

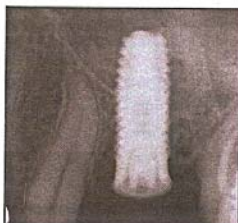

Figure 17. Immediate postoperative radiograph of site #14 demonstrating well-contained sinus graft and 3 to 6 mm of localized sinus floor elevation.

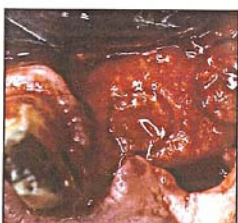

Figure 18. At site #13, 4 mm core will be removed and used in combination with bovine bone to graft 6 mm crestal core after elevation at site #14. Implants will be placed in 5 to 6 months.

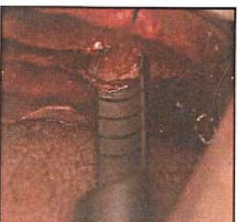

Figure 19. #5 core osteotome is gently malleted around 5 mm crestal core to directly infracture sinus floor, facilitating core elevation.

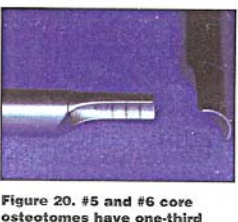

Figure 20. #5 and #6 core osteotomes have one-third round, .5 mm thick curved tip and markings at 2, 4, 6 and 8 mm.

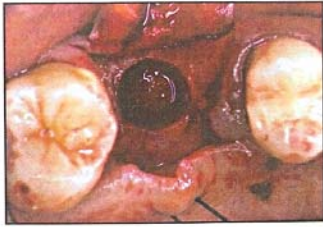

Figure 21. At site #3, 5 mm crestal core has been apically displaced 3.5 mm to original level of sinus floor.

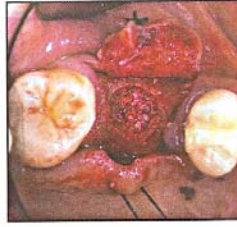


Figure 22. At site #3, 1:1 mixture of autogenous and bovine bone is added to crestal osteotomy and apically displaced to original level of the sinus floor.

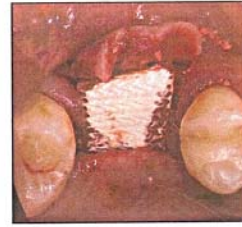


Figure 23. Coverage of crestal core with slowly resorbing collagen membrane.

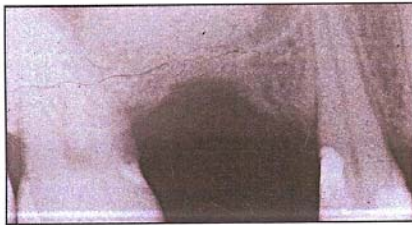


Figure 24. Radiograph at completion of CCE procedure demonstrating 8 to 10 mm of localized sinus floor elevation.

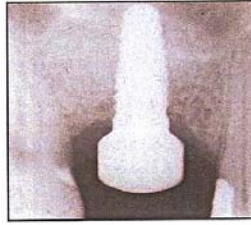

Figure 25. Six months after CCE procedure at site #3, 5 x 11.5 mm tapered screw implant has been placed using single-stage protocol.



Figure 26. Special short (5 x 7mm), porous-surfaced Endopore implants will be used in posterior maxilla to minimize sinus floor elevation.

Using a 5 mm or 6 mm diameter concave-tipped osteotome with 2 mm markings, the core is displaced to the original level of the sinus floor (Figure 21). A composite graft mixture is then prepared using autogenous bone and Bio-Oss (*Osteohealth, Shirley, NY*). The author uses 20% to 60% autogenous graft material harvested directly from the surgical site when possible. The graft mixture is added to the core osteotomy (Figure 22), and the 5 mm or 6 mm diameter osteotome is gently pushed or malleted to the original level of the sinus floor to compress the graft and achieve additional lateral and vertical sinus elevation.

Four to five loads of the graft mixture are placed prior to taking a periapical radiograph to confirm graft containment and to estimate the extent of the augmentation. Grafting is complete once a sinus floor elevation of 8 mm to 10 mm has been achieved. A bioabsorbable collagen membrane (*Ossix, Implant Innovations Inc, 3i, Palm Beach Gardens, FL*) is then placed to cover the core preparations (Figure 23), and the tissues are primarily closed using Gore-Tex sutures (*Gore & Assoc, Flagstaff, AZ*). An immediate postoperative radiograph is taken to confirm graft containment and to determine the extent of sinus floor elevation (Figure 24).

Five to six months later, a periapical radiograph is taken to determine the available bone height prior to implant placement. A similar mucoperiosteal flap is elevated, and osteotomies are prepared with a combination of drills and osteotomes based on localized bone density. The augmented site is generally III or IV bone

quality and presents minimal resistance to drilling. Osteotomes are used to further consolidate the bone and to improve primary implant stability. They may also provide additional sinus elevation, if needed, for the placement of a 10 mm to 11.5 mm long implant. If excellent primary stability is achieved (35 Ncm of insertion torque), then healing caps are immediately placed (Figure 25).

Healing progresses for another five months, at which time, those implants placed using a single-stage protocol are restored or the submerged implants are uncovered and healing caps placed. Multiple implants are subsequently restored with a splinted metal-ceramic prosthesis four weeks later.

Discussion

Elevation of the maxillary sinus floor using an LWO in conjunction with/or without simultaneous implant placement has become a very common procedure in cases where insufficient bone volume is present in the posterior maxilla. It has to be realized, however, that these procedures constitute an invasive surgical intervention with relatively high morbidity and cost.²⁴ The bone-added osteotome sinus floor elevation (BAOSFE) technique^{12,25} and its reported modifications^{13,14,18,22} represent substantially less invasive and less costly alternatives for predictable implant installation in the moderately deficient posterior maxilla with 5 mm to 7 mm of RSBH.

For maxillary sites with adequate ridge width and only 3 mm

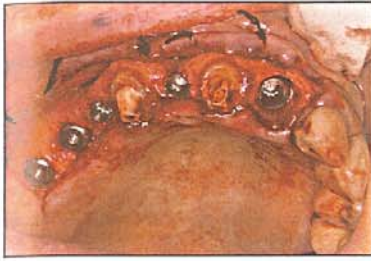

Figure 27. 13 mm long screw-type, Astra ST fixtures have been immediately placed at extraction sites #5, 7 and 9. At sites #3 & 4, 5 x 7 mm Endopore implants have been placed to minimize sinus intrusion.

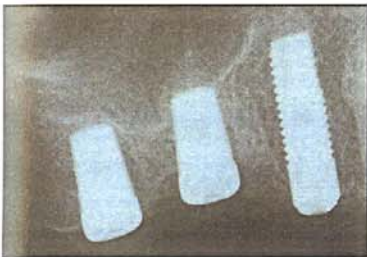


Figure 28. Immediate postoperative radiograph showing 4 x 13 mm Astra ST implant at site #5 and 5 x 7mm Endopore implants at sites #3 & 4. Note minimal sinus floor elevation with sinus floor infrafracture only and no grafting.

to 5 mm of RSBH, modifications to Summers's original future site development (FSD) procedure,¹⁶ reported by Fugazzotto¹⁹ and Toffler,¹⁷ are less traumatic and less costly alternatives to the lateral window osteotomy. These crestal procedures are especially useful at compromised single-molar sites where anatomical restrictions and adjacent teeth complicate a lateral window approach. In the severely deficient posterior maxilla, with 2 mm or less RSBH, crestal procedures become more challenging, time consuming and less predictable. At these sites, a lateral window osteotomy would remain the best method to achieve adequate sinus floor elevation for future implant placement.

The recently reported, improved predictability of textured ITI (Straumann Co., Waltham, MA)^{25,26} and porous-surfaced Endopore (Innova Corp., Toronto, Canada)²⁷ short implants (6 mm to 10 mm) placed in the posterior maxilla should serve to reduce the extent of sinus augmentation necessary for successful implant rehabilitation. This may also increase the demand for less invasive sinus floor elevation that would allow for the placement of implants 6 mm to 10 mm in length (Figures 26 & 27).

As clinicians, we are all striving to make implant treatment cost-effective, short in duration, simple in procedure and highly predictable. The private practitioner wants to rehabilitate most patients without implementing advanced surgical techniques, like extensive sinus grafting or ridge augmentation, because they increase the treatment duration and the costs.²⁷ The utilization of

bio-enhanced shorter fixtures in combination with minimally invasive sinus floor elevation procedures might be helpful in achieving these stated goals with the expedition of treatment and minimization of trauma and cost (Figures 26-28).

Conclusions

For patients resistant to implant placement in the posterior maxilla because they are not willing to undergo extensive sinus floor elevation using a lateral window approach, osteotome-mediated procedures may represent a less invasive treatment option. If the treating clinician or referring dentist is aware of the indications for minimally invasive sinus elevation procedures, many patients may be more accepting of implant rehabilitation in the posterior maxilla.

The simplification of implant placement in the deficient maxillary premolar or molar region using osteotome-mediated procedures can help patients avoid uncomfortable removable appliances or long-span fixed prostheses with increased risks for technical failure.

This author's use of osteotome-mediated techniques has: 1. facilitated implant placement in areas of limited bone height and width; 2. improved initial implant stability through bone compression; 3. improved implant success in the posterior maxilla; 4. simplified sinus floor elevation; and 5. increased case acceptance.²⁸ ■

The author thanks surgical assistants Grisel Crespo, Opal Lumbden, Jazel Best and Tracey Lindsay for their hard work, creativity, support and encouragement.

P C G	PROFESSIONAL	Harold E. Edelman, D.D.S. Speaker Consultant Clinician
	COMPLIANCE	
	GROUP	
<p>They Have been Published...</p> <p>"Guidelines for Infection Control In Dental Health-Care Settings-2003" CDC, MWR December, 2003</p> <p>ATTENTION DENTAL SOCIETIES: <i>Available for your members.</i></p> <p>ATTENTION SPECIALISTS: <i>Available for programs you may provide for your referrers.</i></p> <p>ATTENTION STUDY CLUBS: <i>We come to you in the comfort and convenience of your location. Available for in-office service</i></p> <p>Receive:</p> <ul style="list-style-type: none"> • MCE & AGD Credit • N.Y.S. License: Satisfaction of N.Y.S. infection control requirements. <p>Phone / Fax (631) 716-0046 (Look For Our CE Courses)</p>		

REFERENCES

- Smiler DG, Johnson PW, Lozada JL, et al. Sinus lift grafts and endosseous implants. Treatment of the atrophic posterior maxilla. *Dent Clin North Am* 1992;36(1):151-186.
- Ulm CW, Solar G, Krenrimair G, et al. Incidence and suggested surgical management of septa in sinus lift procedures. *Int J Oral Maxillofac Implants* 1995;10(4):462-465.
- Fugazzotto P. Augmentation of the posterior maxilla: a proposed hierarchy of treatment selection. *J Periodontol* 2003;74(11):1682-1691.
- Jensen OT, Schulman LB, Block MS, Iacono VJ. Report of the Sinus Consensus Conference of 1996. *Int J Oral Maxillofac Implants* 1998;13(Suppl.):1-41.
- Wheeler SL, Holmes RE, Calhoun CJ. Six-year clinical and histological study of sinus lift grafts. *Int J Oral Maxillofac Implants* 1996;11(1):26-34.
- Valentini P, Abensur D, Wenz B, et al. Sinus grafting with porous bone mineral (Bio-Oss) for implant placement: a 5-year study on 15 patients. *Int J Periodont Rest Dent* 2000;20(3):245-253.
- ten Bruggenkate CM. Sinus floor elevation and its predictability. In: Lange NP, Lindhe J, Karring T, eds. *Proceedings of the 3rd European Workshop on Periodontology: Implant Dentistry*. Berlin: Quintessence Publishing; 1999:535-543.
- Toffler M. Site development in the posterior maxilla using osteocompression and apical alveolar displacement. *Compend Cont Educ Dent* 2001;22(9):775-790.
- Smiler DG. The sinus lift graft: basic techniques and variations. *Pract Periodont Aesthet Dent* 1997;9(8):885-893.
- Garg AK, Quinones CR. Augmentation of the maxillary sinus: a surgical technique. *Pract Periodont Aesthet Dent* 1997;9(2):211-219.
- ten Bruggenkate CM, van der Bergh JP. Maxillary sinus floor elevation, a valuable pre-prosthetic procedure. *Periodontol* 2000 2000;17:176-182.
- Summers RB. The osteotome technique: part 3 - less invasive methods for elevation of the sinus floor. *Compend Contin Educ Dent* 1994;15(6):698-708.
- Cavicchia F, Bravi F, Petrelli G. Localized augmentation of the maxillary sinus floor through a coronal approach for the placement of implants. *Int J Periodont Rest Dent* 2001;21(5):475-485.
- Davarpanah M, Martinez H, Tecucianu JE, Hage G, Lazzara R. The modified osteotome technique. *Int J Periodont Rest Dent* 2001;21(6):599-607.
- Nkenke E, Schlegel A, Schultze-Mosgau S, Neukam FW, Wiltfang J. The endoscopically controlled osteotome sinus floor elevation. A preliminary prospective study. *Int J Oral Maxillofac Implants* 2002;17(4):557-566.
- Summers RB. The osteotome technique: part 4 - future site development. *Compend Cont Educ Dent* 1995;16(11):1090-1098.
- Toffler M. Staged sinus augmentation using a crestal core elevation procedure (CCE) to minimize membrane perforation. *Pract Proced Aesthet Dent* 2002;14(9):767-774.
- Fugazzotto PA. Immediate implant placement following a modified trephine/osteotome approach: success rates of 116 implants to 4 years in function. *Int J Oral Maxillofac Implants* 2002;17(1):113-120.
- Fugazzotto PA. The modified trephine/osteotome sinus augmentation technique. Technical considerations and discussion of indications. *Implant Dent* 2001;10(4):259-262.
- Summers RB. A new concept in maxillary implant surgery: The osteotome technique. *Compend Cont Educ Dent* 1994;15(2):152-160.
- Nkenke E, Kloss F, Wiltfang J, et al. Histomorphometric and fluorescence microscopic analysis of bone remodeling after installation of implants using an osteotome technique. *Clin Oral Implants Res* 2002;13(6):595-602.
- Toffler M. Osteotome-mediated sinus floor elevation: A clinical report. *Int J Oral Maxillofac Implants* 2004 ;19(2):266-273.
- Rosen PS, Summers R, Mellado JR, et al. The bone-added osteotome sinus floor elevation technique: multicenter retrospective report of consecutively treated patients. *Int J Oral Maxillofac Implants* 1999;14(6):853-858.
- Bragger U, Gerber C, Joss A, Haenni S, et al. Patterns of tissue remodeling after placement of ITI dental implants using an osteotome technique: a longitudinal radiographic case cohort study. *Clin Oral Impl Res* 2004;15(2):158-166.
- Fugazzotto P, Beagle JR, Ganeles J, Jaffin R, Vlassis J, Kumar A. The success and failure rates of 9 mm or shorter implants in the replacement of missing maxillary molars when restored with individual crowns: preliminary results 0 to 84 months in function. A retrospective study. *J Perio* 2004;75(2):327-332.
- Nedir R, Bischof M, Briaux JM, Beyer S, Szmukler-Moncler S, Bernard J-P. A 7-year life table analysis from a prospective study on ITI implants with special emphasis on the use of short implants. Results from a private practice. *Clin Oral Impl Res* 2004;15(2):150-157.
- Deporter D, Tdescan R, Caudry S. Simplifying management of the posterior maxilla using short, porous-surfaced dental implants and simultaneous indirect sinus elevation. *Int J Perio Rest Dent* 2000;20(5):477-485.
- Toffler M. Localized internal sinus floor elevation. *Astra Tech Insight* 2004;1:16-18.